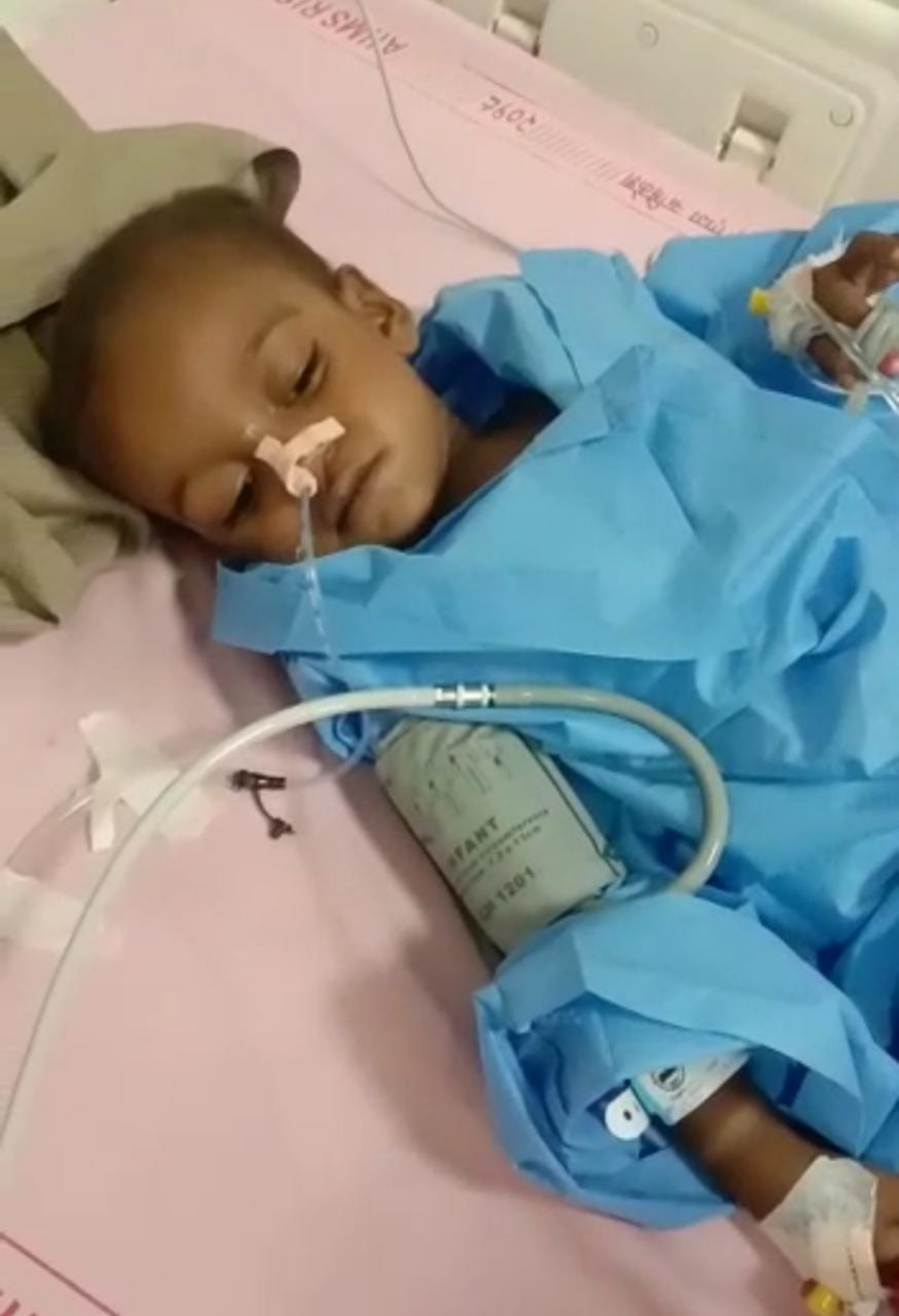



RIMS R

2097

INFANT
1201



31/3/22 A: Recurrent RT wt i lung mets (stage-IV)

LX 1.9 - Reg in disc.

Hgm - 9.3 | 6,200 | 3167 | 5.5 Laktin
TLC

Adv - Review on 21/4/22 E Hgm report

- Syr VITCOFOL / A-2 - (2) 4ml / OD
- Syr cont Syr SEPTRAN 3ml / PO alt days
- Syr EMROT (4ml / 5ml) 2.5ml / PO / Soc.

To Cantids
Kindly issue -

- Syr CAN 500mg - (2)
- Syr ETOF 100mg / 5ml - (3)
- Syr G-11F 300mg - (1)
- Syr VITCOFOL - (1)
- Syr A-2 - (1)
- Syr SEPTRAN - (1)

ABS ward
G. S. Hishar

21.4.22, 22WK ChemD
5/5/22

Hb 90
TALB350

Adv

Pls come

5.5.22

Chang

fever, ↓ oral intake to see Ped Con

- SYP Augmentin DDS 2.5ml BD x 7 days
- SYP MARTRA 3ml x 3 days
- SYP Vitcofol / Septran / A-2

Syp Lethizine 3ml HS x 5 days

Cantids Plz

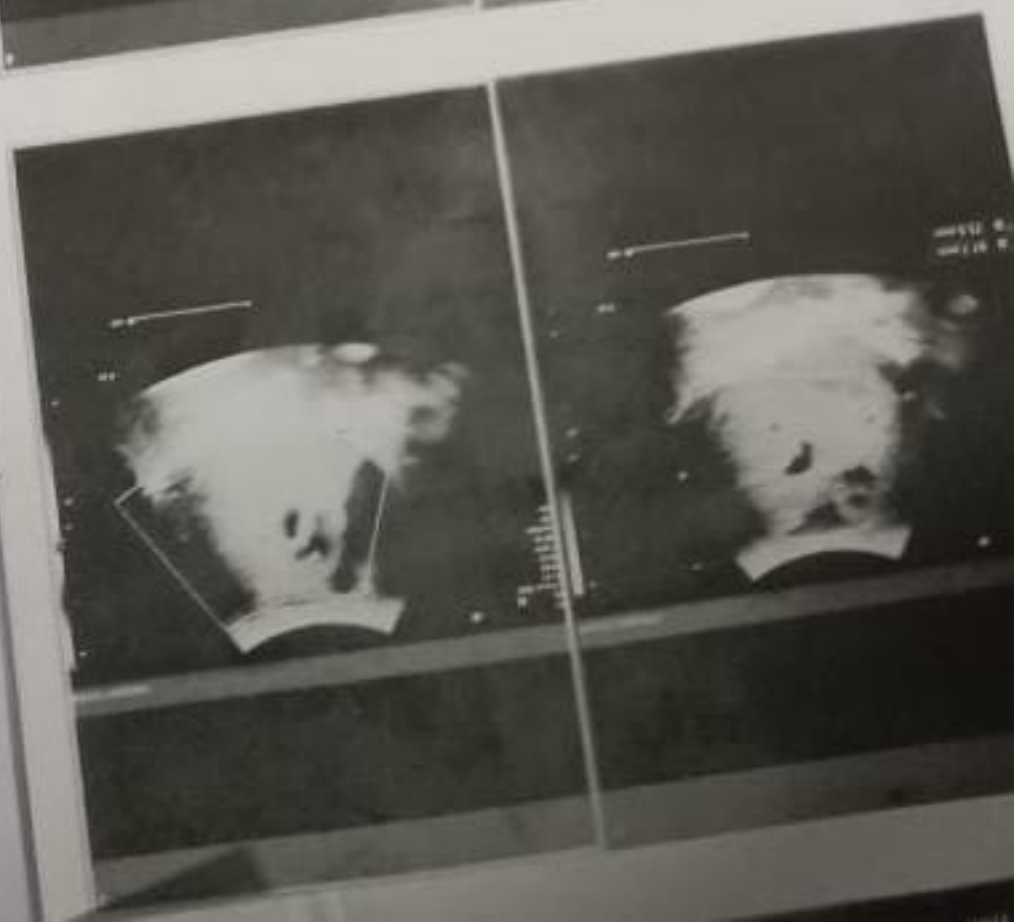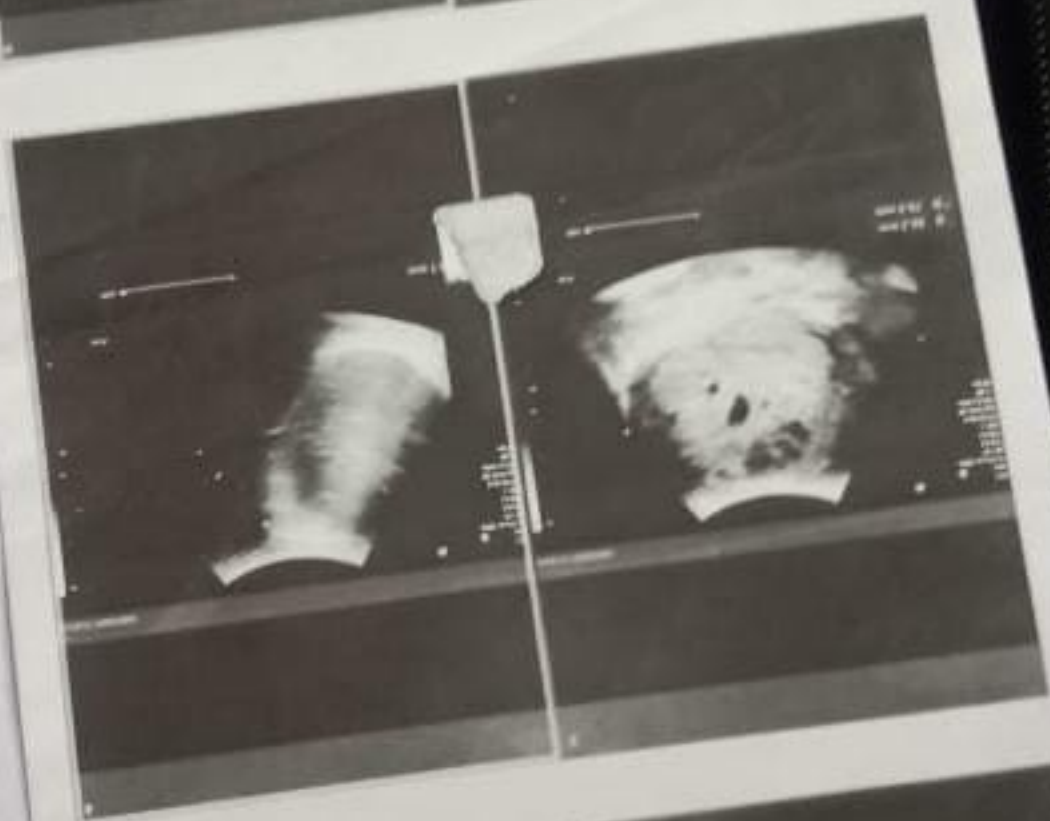
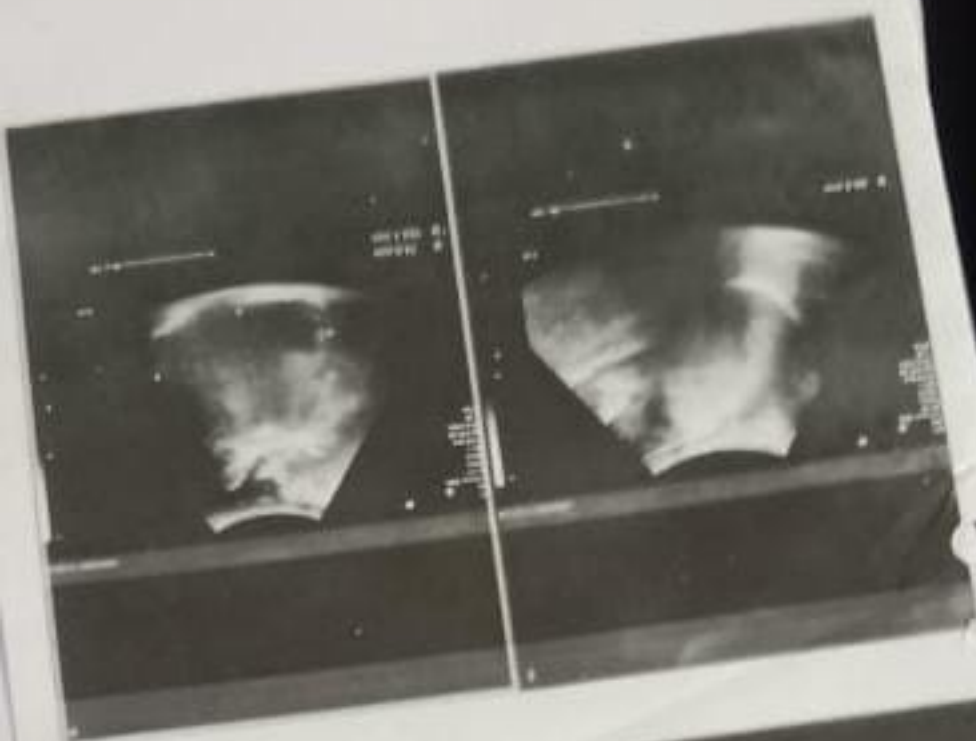- provide SYP Vitcofol (1) SYP A-2 (1)
- (1) VINCERLID 1mg / 1 vial → SYP Septran (1)
- (1) Dactinomycin 1 vial
- (1) Dexamethasone 10mg 2 vials

Handwritten signature

Handwritten notes and signatures:

- use A-2
- SYP vitcofol
- SYP Septran
- SYP

3/3/22 (100)



20/01/22

pacd clms
patient in PT pr procedure subject to (N) blind Smv.
21/2/22

- get CAX
LFT, UFT
chest X-ray


3/2/22

3/2/22

Adv: Dig Vincristine 0.6mg iv today
- Review 10/2/22



21/2/22
please
admit in
PT ward/HMO
ward
[for simulation]
Dr Akanda



10/2/22

pacd oral intake
counting
cloths or vs

Adv:
- ABS ward for BT → chemo week 13.
- Review 3/3/2022 c Hgm.
- HT/WT/chemo calculation in ward pls (no machine)

10/2/22

Caulids pls

- 2mg vincristine 1mg
- 2mg doxorubicin ~~200mg~~
- 2mg Actinomycin D 500µm
- Syp A-2 ① Syp Septtran ①

Syp PUM (250mg/5ml) - 4ml sos if fever
Ak



Department
HOSPITAL PREMISES

DR. B.R.A. IICILAIIMS, NEW DELHI

एकक/Unit
विभाग/Dept.

ICCH No. 264549
Clinic: Radiotherapy Evaluation
Deptt. RADIATION ONCOLOGY
General

Reg. Date: 20/01/2022

Clinic No. 116641/2022

I No./O.P.D. Regn. No.

5245



UHID: 105623495

वय
Age

जन्म तिथि/Date of Birth

105623455

नाम अभिनव अभिनव

Name ABHINAV

SEX: UDAYVEER

Phone No. 972033154

Address: BISAULI DISTT. BADAUN, DELHI, PIN-0, INDIA

Sex/Age: M/27

Room: 4 (Shift Morning)

विराग/Diagnosis

CK-56269

दिनांक/Date

उपचार/Treatment

3.3.22

Planned for RT.
Wk 16 Chemo ~~today~~ being deferred

Adv
Next to see ~~24.3.22~~
c henry on 10.3.22

Shu.

CT
10/3/22

10.3.22

inj Vincristin 0.6mg
inj Actinomycin 200 ug
inj Doxorubicin 14mg (fourteen)
plus
IV stat
overclomyn
c henry on

Next for WK 19

31.3.22

Shu



डा. Dr.

DR. B.R.C. (RCH) AIIMS, NEW DELHI

RCH No. 264549

Reg. Date: 14/10/2021

Clinic: Paediatric Surgery (RCH)

Clinic No. 302104058

Dept. PAEDIATRIC SURGERY (RCH) General



नाम अभिलेख - पिनम

UHID-105623493

Name: A. JHS

/O.P.D. Regn. No.

RT-116643

Sex/Age: M/2Y

जन्म तिथि/Date of Birth

Phone No. 8790111154

Room: 6 (Shift: Afternoon)

Address: BHAULI DISTT. BADAUN, DELHI, INDIA

IRCH

निदान/Diagnosis

Ⓡ Recurrent Wilms Tumor - Stage IV (Lungs, Liver)

दिनांक/Date

11/11/21

उपचार/Treatment

2 1/2 ylm

• Due for WK 5 chemo Regime M

• Wt - 10kg
• Ht - 85cm

• No URI

Hb/TLC/Plt

Adv

11.3/5100/12K

- Inj. Vincristine 0.5mg iv stat.

- Review on 18/11/21 for WK 6 chemo = CBC repeat

- CT dated on 25/11/21

- Cont. Syp. A-Z - 4ml OD

Goswami

- Syp. Vitcofol - 4ml OD

- Syp. Septtran - 4ml on alternate day.

Goswami

3/12/2021.

Kindly register

for RT to Dr. A. Biswas

on 29/01/2022.

C.N. 6

8:30am

Syp
SF-21

AIIMS FREE GENERAL MEDICINE
NAME: A. JHS
DATE: 11/11/21
SIGNATURE: [Signature]

डा. चन्द्रमौली गोस्वामी
Dr. Chandramouli Goswami
Senior Fellow/Junior Resident
Department of Pediatric Surgery
All India Institute of Medical Sciences, New Delhi-29

अंगदान-जीवन का बहुमूल्य उपहार/ORGAN DONATION - A GIFT OF LIFE

O.R.B.O., AIIMS, 26588360, 26593444, www.orbo.org Helpline - 1060 (24 hrs service)

बाहर से आने वाले रोगियों के लिए धर्मशाला की सुविधा उपलब्ध है/Dharamshala facility is available for outstation patients

CR-56269

आर. अम्बेडकर संस्थान रोटरी कैंसर अस्पताल
B.R. Ambedkar Institute Rotary Cancer Hospital
अ.भ.

OPR-6

के रोगी (Patient's Signature)

अस्पताल (Hospital)

MISES

DR. B.R.A. BHAGAT, NEW DELHI
IRCH No. 264549
Class Post Surgery Clinic
Dept. PAEDIATRIC SURGERY/IRCH
General
Name अभिनव अभिनव
Name ABHINAV
SO. KIDDER
Phone No. 872803374
Address BHAGATI DEVI, BAHAMAN, DELHI, PIN-110018



Reg. Date: 14/11/21
Class No. 202 014
n. No. _____
Date of Birth _____

अभि (Patient's Name)

रोग/ Diagnosis

Request for further treatment (local/chemo/long term)

दिनांक/ Date

उपचार/ Treatment

→ NFD (14/7/21) - N/A
→ No chemo given
→ III - stage T favorable
histology (w/ biopsy not done)

clo/w Prof Sandeep Aggarwal

- To start Regim M chemotherapy
- To see c/hgm for next chemo
21/10/21

To ensure HSP shield

Signature

6/45
11/11



डा. बी. आर. अम्बेडकर संस्थान रोटरी कैंसर अस्पताल
The Rotary Cancer Hospital
/A.I.I.M.S. HOSPITAL

OPR-6

DR. B.R. AMBekar, A.I.I.M.S., NEW DELHI
H No. 264549
Paed Surgery Clinic
PAEDIATRIC SURGICAL WING
अभिनव अभिनव
ABHINAV
UDAYVEER
No. 9720035554
BISAUJI DISTT. FADAUN, DELHI. Pin-0, INDIA

बोरोविं पंजीकृत सं/O.P.D. Regn. No. _____

लिंग Sex	आयु Age	जन्म तिथि/Date of Birth

निदान/Diagnosis Δx : Recurrent @ Wilms Tm & bilat lung and liver mets and RPLNs

उपचार/Treatment
49/B Dr. A. Biswas

दिनांक/Date
29/1/22
6/25
10/2

- 2yr child
- Initial stage III (Inadequately treated & Sx alone at AIIMS Rishikesh on 14-July-2021)
- Recurrent @ WT & bilat lung and liver mets and RPLNs
- Post WII chemo (Reg-M) last on 27/1/22
- RA-CT scan → (good) PR

Provisional Plan

- RT to recurrent tm bed [21.6Gy/12#/12 working days] } ↓ GA Room (40)
- Anns for boost (9Gy/5#/5 days)
- Whole lung irradiation (12Gy/8#/8 working days)

Adv

- Paediatric Sx review opinion for Sx for residual lesion on abd and lung metastatic to
- Anesthesia clearance Room (60) & Img./Bcm, CXR PA view

Surgical notes in file

Thursday I.R.C.H. - Room 6

DFRT
↓
details & contact number noted & entered in Pediatric register

अंगदान-जीवन का बहुमूल्य उपहार/ORGAN DONATION - A GIFT OF LIFE

O.R.B.O., AIIMS, 26588360, 26593444, www.orbo.org Helpline - 1060 (24 hrs service)

↓ बाहर से आने वाले रोगियों के लिए धर्मशाला की सुविधा उपलब्ध है/Dharamshala facility is available for outstation patients

Patient will be called telephonically when slots open up. *Sofam JR Red Owl*



डा. बी. ओर. अम्बेडकर संस्थान रोटरी कैंसर अस्पताल
Dr. B.R. Ambedkar Institute Rotary Cancer Hospital
S. HOSPITAL

OPR-6

DL IIR.A. IICHA IIMS, NEW DELHI

Department
D IN HOSPITAL PREMISES

IRCH No. 264549

Reg. Date-14/10/2021

Clinic: Paed Surgery Clinic

Clinic No. 202104034

Dept. PAEDIATRIC SURGERY-IRCH



UHID-105623495

एकक/Unit

नाम अभिनव अभिनव

वीकृत सं/O.P.D. Regn. No.

विभाग/Dept.

Name ABHINAV

SDA UDAYVEER

Phone No. 9720035554

Address BISAULI DISTT. BADAUN, DELHI, INDIA

वयु
Age

जन्म तिथि/Date of Birth

10 R.O.C.H

105623495

Wilm's tumor

निदान/Diagnosis

उपचार/Treatment

दिनांक/Date

16/12/21

A has mild fever.

Platelet 16000

PC-600

Adm.

2/Was Agarwal

Syph Grocin 100 mg x 2 days

Syph Augmentin 100 mg x 5 days

RECEIVED
30/12/21

16/12/21 (cont) Tongue signs explained.
Remain casually immunized

Review 20/12/21 empty

30/12/21

10.2/968/350K

Asymptomatic

डॉ. विशेश जैन
Dr. Vishesh Jain

अपर आचार्य/Additional Professor
विभाग/Department of Paediatric Surgery
आर.बी.ओ. संस्थान, आई.आई.एम.स. नई दिल्ली-29

Additional Professor
Department of Paediatric Surgery
A.I.I.M.S. New Delhi-29

Adm
Syph Grocin
Syph A 2
Syph Augmentin

Adm
- Review in week 9 due
- High VCR as syph is stat
- cot A 2 / Grocin / Augmentin

30/12/21
Review 6/1/22

अंगदान-जीवन का बहुमूल्य उपहार/ORGAN DONATION - A GIFT OF LIFE
O.R.B.O., AIIMS, 26588360, 26593444, www.orbo.org Helpline - 1060 (24 hrs service)

बाहर से आने वाले रोगियों के लिए धर्मशाला की सुविधा उपलब्ध है/Dharamshala facility is available for outstation patients

30/12/21
Mj VCR
Kamlesh
Jais

Dr. Vishesh Jain
Professor
Dept. of Paediatric Surgery

CONSULTING ROOM NO - 1051
BOOK NO - 16
Clinic: Pediatric Surgery
Days: MON, WED, FRI
LAST VISIT DATE: 06/08/2021

FILE ID - 21000298026151621



OUTPATIENT RECORD
Re-visit

Name: MASTER, ABHINAV
Department: Paediatric Surgery
Dept No.: 2021/096/0000773
Date of Registration: 06-08-2021 10:02:32 AM
Unit: 1
Age: 2Y 24D
Billing Type: General
Mobile No: *****15
Address: katholi, an
Patient Type: NON MLC

Fee: 0.00
Sex: M
S/O: Indrajit
Email:
Occupation: null
Prepared by: Mrs. Ruchi Rani

Q. 5001.
C/S / B. paediatric's surgery
operated case 13/7/2021,
Wilm's tumor

HPE report

↓
Right Kidney c/water
Wilm's tumor
favourable
Histology
Right Kidney
stage - 1

Clg
- fever on & off
- no fresh complaint

Adv
- Review in OPD
after 13 August
- Medical oncology
opinion.

Luwrao
4A VFAV
en 100m?

- collect discharge
from ward.



CONSULTING ROOM NO : Floor
TOKEN NO : 45
Clinic: Medical Oncology
Days: MON, TUE, THU, FRI
LAST VISIT DATE: 06/08/2021

EHR ID : 21000298026151621



OUT PATIENT RECORD
Re-visit

Name : MASTER. ABHINAV
Department : Department of Medical Oncology-Haematology
Dept No. : 2021/088/0004548
Date of Registration : 06-08-2021 12:02:17 PM
Unit : I
Age : 2Y 24D
Billing Type : General
Mobile No : *****645
Address : kaitholi , an
Patient Type:NON MLC

Fee: 0.00
Sex:
NO adaysent
Email:
Occupation : null
Prepared by Ms. Meenakshi Chaudhan

6/8/21

2 years old ♂

Δ: Stage I Wilms tumor, (R)

P) upfront sx ——— exp. lap & upfront
(L) radical nephrectomy
on 14/7/21.

Now referred to med onco for opinion
on chemotherapy. (Cediraner?)

Plan

- D/w Dr. Amit Sir.

RT opinion | for admission | for
planning adjuvant chemo
RT registration | admission

MS
Sun



DISCHARGE SUMMARY

OPD No.: 2107090125 IPD No.: 210709005 DEPARTMENT: Pediatrics
 (Referral)
 DATE OF ADMISSION: 09/7/21 DATE OF DISCHARGE: 12/7/21
 NAME OF THE PATIENT: Mr./Ms./Master ABHI S/O UDAYVEER
 S/o, W/o, D/o: _____
 AGE: 2 years Yrs./Mths. SEX: MALE/FEMALE M
 ADDRESS: Village - Kaittholi, BISOIL, BADAUN, UP, India.
 CONSULTANT INCHARGE: DR. Anshuman Singh
 CLINICAL DIAGNOSIS: Wilms tumor

CLINICAL SUMMARY / PRESENTATION: pt came to us w/ c/o swelling over Rt. Side of Abd., ↓ in Appetite x 1 Month. on Admissⁿ pt. vitals are Stable, P/A - Swelling ⊕ in Lt Hypocondrium extending to rt lumbar region BP - 104/60 mmHg. on Admissⁿ pt. treated with I/V fluid and Antibiotic, on USG - Rt sided Renal Mass = cystic component +ve, In CECT - large Heterogeneity enhancing solid cystic space occupying lesion arising from lower pole of Rt. kidney suggestive of malignant Neoplasm (w/ metastases) pt. refer to Higher center for further Management.


INVESTIGATION DONE:

Hb - 10.5 TLC - 15470 W - 63 L - 32 E - 0 M - 05 B - 0 PLT count - 4.46 Total RBC - 4.03	Albumin - 3.6 Globulin - 3.5 A/G - 1.03 Urea - 19 Cr - 0.5 Uric Acid - 3.8 Ca - 9.5 Phosph - 4 ALP - 106 Na - 141	<div style="border: 1px solid black; padding: 5px; display: inline-block;">LFT</div> BT - 0.3 BD - 0.1 BI - 0.2 K - 5.2 Cl - 103 CRP - 2.68	<div style="border: 1px solid black; padding: 5px; display: inline-block;">Urinalysis</div> Vol - 10 Color - pink/white Appearance - Clear pH - 6 Albumin - + Sugar - -ve RBC - Not pus cell - 10-12 Epithelial - 2-3 Bacteria - not seen Crystal - Not Cast - Not
--	--	---	--

P.T.O.

कॉपी नंबर

Indian Institute of Medical Sciences Rishikesh



14 AUG 2021

09

OPD Bill Receipt
Original

Receipt No :
Receipt Date :
Billing Type :

CASHBOOK-76867/202122
13/08/2021 01:59 PM
GENERAL

CHID : 20210056766
Name : MASTER, ABHINAV
Address : S/O Udayveer Kashhotan
Age & Sex : 2 Yrs 1 Mon 0 Days - MALE
Dept. Name : Department of Medical Oncology-Haematology
Payment Details : Payment Mode : Cash
A/C ID :

Contact No :
N

83XXXXXX45

Service Details:

- 1. MICROBIOLOGY AEROBIC CULTURE AND ANTIBIOTIC SENSITIVITY TEST FOR URINE
- 2. PATHOLOGY COMPLETE BLOOD COUNT
- 3. PATHOLOGY URINE ROUTINE AND MICROSCOPY EXAMINATION

Sl. No.	Qty	Rate	Amount	Discount	Net
1	200	200	0	200	
2	25	25	0	25	
3	25	25	0	25	

Total Amount : Rs. 250
Discount : Rs. 0
Net Amount : Rs. 250

Amount in Words:
Two Hundred Fifty Rupees And Zero Paise

[Authorized Signature]
Mr. Deepak Singh

2 copy

LABORATORY OBSERVATION REPORT

UHID: 20210056766 Reg Date: 13/07/2021 08:20 AM
 Patient Name: Master. ABHINAV Age: 2 years 1 month 1 day
 Sex: Male Department: Department of Medical Oncology
 Unit Name: Haematology
 Lab Name: PATHOLOGY Unit Incharge:

Sample Details: PAT-140821014 (Urine) Collection Date :14/08/2021 08:47 AM Lab Ref No :10772

Report Generated on: 17/08/2021 09:02 AM

Test Name : URINE ROUTINE AND MICROSCOPY EXAMINATION (Template : urine routine)
 Department of Pathology and Lab Medicine

Urine Routine and Microscopic Examination

ROUTINE	RESULT	MICROSCOPY	RESULT (cells/HPF)
Colour	Pale Yellow	Pus Cells	0-1
Clarity	Clear		
Specific Gravity	1.030	Epithelial Cells	0-1
pH	6.0		
Proteins	Negative	Red Blood Cells	Nil
Glucose	Negative		
Bilirubin	Negative	Casts	Nil
Urobilinogen	Normal		
Blood	Negative	Crystals	Nil
Leukocytes	Negative		
Nitrite	Negative		
Ketones	Negative		
Any other			

Interpretation Chart

Grade	+	++	+++	++++
Protein (mg/dl)	30	100	500	NA
Glucose (mg/dl)	50	100	300	1000
Ketone (mg/dl)	16	52	156	NA

Verification Comment: Dr. Kranthi
 Junior Resident



ALL INDIA INSTITUTE OF MEDICAL SCIENCES, RISHIKESH
DEPARTMENT OF RADIO-DIAGNOSIS AND IMAGING

Name of the Patient:	ABHINAV 2y1M	Cr No.:	20240056766
Ref. De: tt.	Paed. Sw	Date:	13/8/2021

USG KUB

RIGHT KIDNEY: Normal in Size ~~shape and echotexture. Cortical-medullary differentiation is maintained. Cortical echotexture appears to be normal. No hydronephrosis or calculus seen.~~ ~~Not visualised - post nephrectomy status. No collection of focal lesion is seen at post operative bed at the time of scan.~~

LEFT KIDNEY: Normal in size ^{5.7 x 3.2 cm} shape & echotexture. Cortical echotexture appears to be normal. Cortical-medullary differentiation is maintained. No hydronephrosis or calculus seen.

URINARY BLADDER: distended. wall thickness is normal. no internal echo is present.

OTHERS: -


No free fluid seen.

IMPRESSION: - Right kidney not visualised - post nephrectomy status.

my
Dr. Dhori, JR

G
Dr. Garima, SR

18



All India Institute of Medical Sciences, Rishikesh

UHID: 20210056766

CONSULTING ROOM NO
Floor
TOKEN NO: 8
Clinic: Medical Oncology
Days: MON, TUE, THU, FRI
LAST VISIT DATE: 17/08/2021

EHR ID: 21000290026151621



OUTPATIENT RECORD
Re-visit

Name: MASTER, ABHINAV
Department: Department of Medical Oncology-Haematology
Dept No.: 20210080004548
Date of Registration: 09-10-2021 09:01:05 AM
Age: 23 2M 20D
Height Type: General
Mobile No.: 989609426
Address: Kashi, UP
Patient Type: SON/MLC

Fee: 1000
Sex: Male
S/O: Indrajit
Initial: [unclear]
Occupation: null
Prepared by: MRS. Reema Pathak

24yr old, ♂
Stage - I Wilms' tumour,
port Sp → (R) Radical Nephrectomy
14/7/21.

↓
Case discussed in T. Board. In Aug 2021
Adv - to Flt in met. one OPD of USG Abd
after 3 months

USG Abd 21/10/21 → Iso echotc SOL in Liver Rt lobe
4x3.7cm. ? Nature

DEPARTMENT OF PEDIATRIC SURGERY
ALL INDIA INSTITUTE OF MEDICAL SCIENCES
NEW DELHI-110029
DISCHARGE SUMMARY

NAME	ABHINAV	AGE	2Y	SEX	Male
FATHER'S NAME	UDAYVEER	DOA	05/04/22	CR No.	H-309546-22
ADDRESS	BISAULI DISTT. BADAUN			UHID No.	105623495
		DOD	10/04/22	TELEPHONE	9720035554
DIAGNOSIS:	RIGHT RECURRENT WILMS TUMOR WITH B/L LUNG AND LIVER METS				
Ward course	Child was admitted for week 19 Chemotherapy. Week 13 chemo administered without any complications.				
ADVICE ON DISCHARGE:	<ul style="list-style-type: none"> • Laminare discharge summary. • Continue A-Z/vitcofol/Septran. • Inj. Filgastrim 65 mcg (0.22ml)- s/c 4 doses daily for 4 days = 300mg 1 vial • Follow Up in IRCH (room No 6) on 28/04/22 on Thursday with CBC report. 				
ADMISSION SR	Dr Dhruv	MANAGING SR	Dr Dhruv		
CONSULTANT	Prof Sandeep Agarwala	FOLLOW UP VISIT	Follow Up in IRCH (room No 6) on 28/04/22 on Thursday with CBC report		

DATE: 10/04/22

SIGNATURE Agarwala

CANKIDS...KIDSCAN
 CKID...56269...
 No.-100 Social Support Team

10/4/22
 Approved by
 Basheer S. W
 Impey P. R



भारत सरकार

Government of India



उदयवीर

Udayveer

जन्म तिथि / DOB : 01/01/1997

पुरुष / Male



2032 9918 4734

आधार - आम आदमी का अधिकार



Department Of Pathology
All India Institute Of Medical Sciences
Delhi

Tel: +91-11-26588500/26588700, Fax: +91-11-26588500/26588700

Patient Name: Abhinav F/H Name: Udayveer Age/Sex: 2 Y/Male Clinic/Dept/Unit: Dr. B.R. A. IRCH/Unit 1 Reg Date: 28-10-2021	Acc. No: 2130076 Hosp. Reg. No.: 264549 UHID No.: --- Consultant Incharge: Dr. N/A Reporting Date: 13-11-2021
--	--

Histopathology Report

Report Findings:

- Received two HE stained slide and two paraffin blocks for review as right nephrectomy . (No. G-1162/21).

-Sections examined show extremely poorly preserved tissue, which however shows features of a triphasic Wilm's tumor infiltrating the capsule but not breaching it. The tumor is infiltrating the renal sinus fat and wall of the pelvic blood vessels. The tumor cells are immunopositive for PAX8. While P53 is negative, WT1 is Non contributory due to poor preservation of tissue.

-There is no evidence of anaplasia in the sections examined.

SIOP stage: II

Note: The above features are reported within limitation of the material submitted.

Reporting Incharge: **Dr. Aanchal Kakkar**

Reporting SR: **Dr. Arun Kumar Panda**
 Verify By: **Dr. Sagir Akhtar**

HPE (14/7/21): Wilm's tumor, favourable histology, Right kidney, stage 1

Margins free of tumor

Ureteral margins free of tumor

Hospital stay: Child was admitted for evaluation and management of metastatic Wilms tumor and is being referred to AIIMS Delhi for further management.

Condition at discharge: Stable, taking full diet, passing urine and stool.

Treatment at Discharge:

1. Syp Iron 2.5ml once day to continue
2. Syp MVI 2.5 ml once a day to continue
3. Syp Ca+ Vit D3 2.5 ml once a day to continue

Follow up:

- In emergency if fever, pain, hematuria. Can contact on 9997522082 if needed.

Doctor's Signature: -

Tajinder
Resident

u/w by

Dr. Jagdish B
Junior Resident
Department of Paediatric Surgery
AIIMS, Rishikesh

Manish

Consultant



302/21/9 (1704)

DEPARTMENT OF RADIO-DIAGNOSIS & INTERVENTIONAL RADIOLOGY
ALL INDIA INSTITUTE OF MEDICAL SCIENCES
A.I.I.M.S., NEW DELHI-110029

Patient Name : *Abhinava*

Age/Sex : *27/M*

Date : *13/01/18*

USG No. *D8686*

Ward/OPD

Clinical Details : *90 wt loss tumor & heavy ascites*

ULTRASOUND ABDOMEN

Liver : *9.6 cms* Normal in size and echotexture. No focal lesion/IHBRD

Gall Bladder : Normal in wall thickness. No calculus seen.

CBD/PV : Normal in calibre.

Pancreas : Normal in bulk and echotexture. MPD not dilated.

Spleen : *7 cms* Normal in size and echotexture. No focal lesion seen.

Bilateral Kidneys : Normal in size and echotexture. No calculus/Hydronephrosis seen.

Urinary Bladder : ~~Normal~~ *partially distended & mildly twisted*

No Free fluid seen. *Bladder - 7 cms. no intraluminal echoes. U-R canal*

Impression :

(Signature of Radiologist)



डा. बी. आर. अम्बेडकर संस्थान रोटरी कैंसर अस्पताल
Dr. B.R. Ambedkar Institute Rotary Cancer Hospital
A.I.I.M.S. HOSPITAL

OPR-6

Patient Department
PROHIBITED IN HOSPITAL PREMISES

DL B.R.A. IICILAHIMS, NEW DELHI

IRCH No. 264549

Reg. Date: 14/10/2021

Class: Paed Surgery Clinic

Clinic No. 2021/4058

Deptt. PAEDIATRIC SURGERY-IRCH



General

UHID-105623495

नाम अभिनव अभिनव

Name ABHINAV

Sex/Age: M/2Y

S/O: UDAYVEER

Room: (Shift: Afternoon)

Phone No. 9720035554

Address: BISAULI DISTT BADAUN, DELHI, Pin 0, INDIA

रोगी का पंजीकृत सं./O.P.D. Regn. No.

Sex	Age	जन्म तिथि/Date of Birth
		IRUN

निदान/Diagnosis

उपचार/Treatment

दिनांक/Date

05/05/22

Due for wk 22 Reg M chemotherapy
Hgb (05/05/22) - 9.8 $\frac{3700}{607}$ < 2.51 Lable

CANSAIDS


Please issue

- 1x Vincristine 1mg @ vial
- 1x Doxorubicin 0.5mg @ vial
- 1x Doxorubicin 10mg @ vial
- Syg Septan
- Syg Vitcofol } Bottle each
- Syg Ato Z
- Syg Emstat

Adv

- wk 22 Reg M chemotherapy to be given
- F.U. on 26/05/22 i.e. fresh Hgm/RFT/LFT

Dr. P. S. Singh



R

- 1x VCR 0.6mg | 2x | stat
 - 1x Actinomycin - 0.2mg | 2x | stat
 - 1x Doxorubicin - 10mg | 2x | stat
- over 10

CT
5/5/22

R

अंगदान-जीवन का बहुमूल्य उपहार/ORGAN DONATION - A GIFT OF LIFE
O.R.B.O., AIIMS, 26588360, 26593444, www.orbo.org Helpline - 1060 (24 hrs service)

बाहर से आने वाले रोगियों के लिए धर्मशाला की सुविधा उपलब्ध है/Dharamshala facility is available for outstation patients



Department of Paediatric Surgery
Discharge summary

Name: Master Abhinav	Age/Sex: 2 Years/ Male	Address: KAITHOLI, AN, UTTAR PRADESH, INDIA Father name: Udayveer Phone number: 8392882645	Ward/Bed- IPD/ PAEDIATRIC SURGERY																																										
DGA- 13/07/2021	DOD- 20/07/2021	Consultant: Dr. Manish K Gupta	UHID No. 20210056766																																										
<p>Brief History: Informant, Mother reliable, 2 years old male child came with C/O mass in right flank noticed since last 1 month, gradually increasing in size, not associated with pain H/O fever 2-3 episodes, over 1 month, low grade, relieved on its own No h/o vomiting, haematuria, dysuria, constipation, breathlessness. Normal bowel/ bladder habit. No significant family history.</p> <p>Examination: Conscious, BP: 87/48 mmHg PR: 96 /min, TEMP: 98.4 F RR: 26 /min, Weight: 10 kg No pallor, icterus, cyanosis, lymphadenopathy. General examination: WNL Systemic examination: WNL Abdominal examination: Abdomen distended, Right flank fullness seen. Firm mass palpable 2cm below right costal margin from right hypochondrium to right iliac fossa. Non-tender. ~1 cm from midline. BS present.</p>		<p>Physical Examination & Investigations: -</p> <table border="1"> <thead> <tr> <th>Date</th> <th>13.7.21</th> <th>16.7.21</th> </tr> </thead> <tbody> <tr> <td>SpO₂</td> <td>10.94</td> <td>10</td> </tr> <tr> <td>TLC</td> <td>9.817</td> <td>6.31</td> </tr> <tr> <td>PLT</td> <td>473.5</td> <td>452</td> </tr> <tr> <td>PT/INR/A</td> <td>11.7/0.8</td> <td></td> </tr> <tr> <td>PTT</td> <td>5/33.5</td> <td></td> </tr> <tr> <td>B.U/ S.Cr</td> <td>12.7/0.5</td> <td>14/0.3</td> </tr> <tr> <td></td> <td>9</td> <td></td> </tr> <tr> <td>Na/K/Ca</td> <td>135.1/4.6/9.18</td> <td>142/4.88/9.5</td> </tr> <tr> <td>Bilirubin T/D</td> <td>0.24/0.11</td> <td></td> </tr> <tr> <td>SGOT/SGPT</td> <td>26.2/ 9.2</td> <td></td> </tr> <tr> <td>ALP/GGT</td> <td>250/13.6</td> <td></td> </tr> <tr> <td>TP/ Alb</td> <td>6.7/4.51</td> <td></td> </tr> <tr> <td>Viral markers</td> <td>NR</td> <td></td> </tr> </tbody> </table> <p>COVID TEST: Negative for mother and patient. Procalcitonin (13/6/21): 47.42 D Dimer (12/6/21): 6.24</p>		Date	13.7.21	16.7.21	SpO ₂	10.94	10	TLC	9.817	6.31	PLT	473.5	452	PT/INR/A	11.7/0.8		PTT	5/33.5		B.U/ S.Cr	12.7/0.5	14/0.3		9		Na/K/Ca	135.1/4.6/9.18	142/4.88/9.5	Bilirubin T/D	0.24/0.11		SGOT/SGPT	26.2/ 9.2		ALP/GGT	250/13.6		TP/ Alb	6.7/4.51		Viral markers	NR	
Date	13.7.21	16.7.21																																											
SpO ₂	10.94	10																																											
TLC	9.817	6.31																																											
PLT	473.5	452																																											
PT/INR/A	11.7/0.8																																												
PTT	5/33.5																																												
B.U/ S.Cr	12.7/0.5	14/0.3																																											
	9																																												
Na/K/Ca	135.1/4.6/9.18	142/4.88/9.5																																											
Bilirubin T/D	0.24/0.11																																												
SGOT/SGPT	26.2/ 9.2																																												
ALP/GGT	250/13.6																																												
TP/ Alb	6.7/4.51																																												
Viral markers	NR																																												

USG Abdomen (10/7/21)- done outside:

Right kidney is nearly completely replaced by a heterogeneously hyperechoic, well defined lesion having both solid and cystic components measuring approx. 11x7cm, the lesion shows mild vascularity. There is a relative sparing of the inferior pole of right kidney

Impression: Right sided renal mass with solid and cystic components- suggested possibility of Wilm's tumor