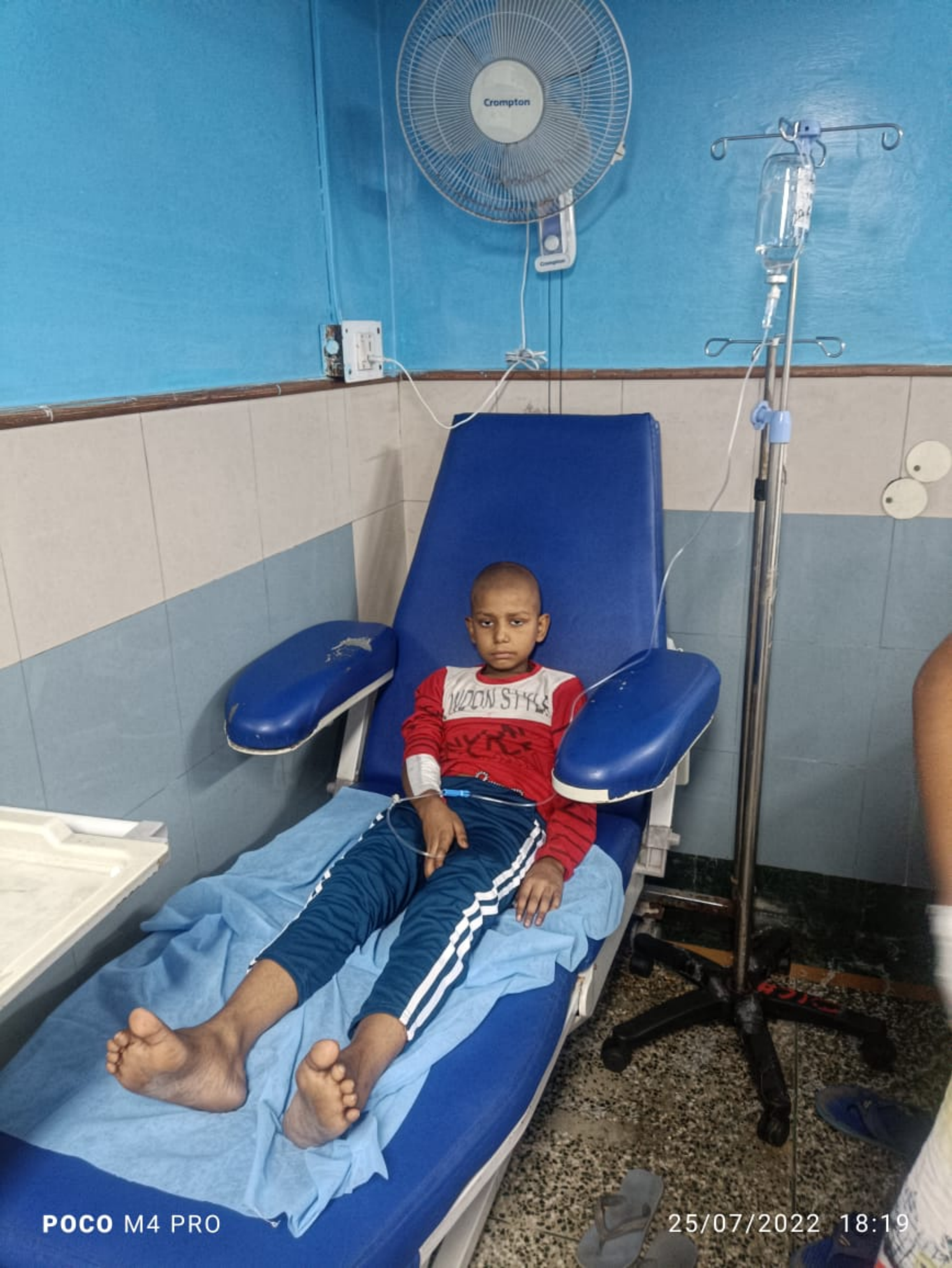





भारत सरकार
Government of India



दिव्यांश

Divyansh

जन्म तिथि/DOB: 11/10/2012

पुरुष/ MALE

Issue Date: 05/10/2021

3928 6651 4470

VID : 9129 4481 4431 1748

मेरा आधार, मेरी पहचान



डा. बी. आर. अम्बेडकर संस्थान रोटरी कैंसर अस्पताल
Dr. B.R. Ambedkar Institute Rotary Cancer Hospital
अ भा आ सं. अस्पताल / A.I.I.M.S. HOSPITAL

OPR-6

DR. B.R.A. IRCH, AIIMS, NEW DELHI

UHID: 105911753



IRCH No. 272521

General

नाम दिव्यांश दिव्यांश
Name DIVYANSH

S/O- RAJEEV

Sex/Age M/10Y

Phone No. 9990957398

Address G NQ-4, DAULAT PURA GZB, UTTAR PRADESH, INDIA

Out Patient Department
NOTHING PROHIBITED IN HOSPITAL PREMISES

272521

बॉरोयिं पंजीकृत सं/O.P.D. Regn. No.

लिंग Sex	आयु Age	जन्म तिथि/Date of Birth

निदान/Diagnosis

B-NHL

दिनांक/Date

उपचार/Treatment

20/7/2022

CC#2 - From 25/7

कमरी 15

1. Inj. VCR 1.5mg IVP - d2 (25/7)

2. Inj. DEXONA 3mg in 100ml NS

d1 - 3

(25/7, 26/7, 27/7)

3. Inj. ARA-C in 100ml NS BD

d1 → 2g - 2g (25/7)


d2 → 2g - 2g (26/7)

4. Inj. VP-16 in 50ml NS

d2 → 250mg (26/7)

d3 → 200mg (27/7)

P10



अंगदान-जीवन का बहुमूल्य उपहार/ORGAN DONATION - A GIFT OF LIFE

O.R.B.O., AIIMS, 26588360, 26593444, www.orbo.org Helpline - 1060 (24 hrs service)

बाहर से आने वाले रोगियों के लिए धर्मशाला की सुविधा उपलब्ध है/Dharamshala facility is available for outstation patients

Inj Rituximab from daycare - 21/6/22

10

~~RITUXIMAB 400mg~~

Pre-medication:

Ij. Anal 1cc IV stat

Ij. Hydrocort 50mg IV stat

T. PC M 250mg P.O stat

↓

Ij RITUXIMAB 400mg in 500ml NS IV over 6 hours
 Start @ 25ml/hr, increase by 25ml/hr every hour
 if tolerating well

~~Tab LEUCOVORIN 20mg~~

Tab Leucovorin 20mg - 20/6/22 5pm - 5pm
 20/6/22 11pm - 11pm

Plenty of fluids → उसादा पानी

Continue Septran/Aurin → जाँची रखनी है

H/b

Burkitt lymphoma. P/Sx (Jan '22), R4.

Ongoing VCR (since H/stx)

- c/o dysphagia over B/L upper part of neck since 2 days.
- c/o fever since 1 day, also cough with yellowish sputum.
- not a/w burning micturition

O/E. Oral mucosa (N), - No soreness

RS - No added sounds, B/L FE (+)

- currently not on any analgesia.

Rx

Syp mucaine gel 2tsp BD.
Timple gargle [viscous lignocaine - (1 teaspoon)
Benadryl - (1 teaspoon)
0.2% sodium bicarbonate - (1 pinch)

Refrain from oral intake for 30 min

✓ Betadine gargle. TDS

→ Paracetamol 250mg BD. 500mg 1/2 tab BD.

→ emiset 1mg 1/2 tab BD.

Syp Gritinex 1 tsp BD.

Saline nebulisation

Kindly get medicines from generic pharmacy

Dr. Jyoti K. Menon
SENIOR RESIDENT
Dept. of Onco-Anaesthesia & Palliative Medicine
Jawahar Institute of Postgraduate Medical Education & Research (JIPMER), New Delhi-29

ANMS FREE GEN. JC PHARMACY
MEDICINE RECEIVED
DATE: 27/1/22
SIGN: [Signature]

[Signature]
R/A not done



UHID No: 105911753

(DEPT. OF EMERGENCY MEDICINE)

दिनांक DATE: 01/06/2022

समय TIME: 12:27:12 PM

NON-MLC

आपातकालीन नं. (Emergency No): 2022/030/0041827

आयु AGE: 10 years 1 months 20 days

लिंग / SEX: M

नाम NAME: MR. DIVYANSH DIVYANSH

S/O: RAJEEV

पता ADDRESS:

मकान संख्या H.NO:

शहर/प्रखंड CITY/BLOCK:

राज्य STATE:

मोबाइल MOBILE NO:

G NO-4, DAULAT PURA GZB

UTTAR PRADESH

9990957398

गली / मुहल्ला STREET/MOH:

पिन PIN:

दूरभाष सं. PHONE NO:

स्थान Location:

Criticality: Red / Yellow / Green

9990957398

Paediatrics Emergency

द्वारा BROUGHT BY: Relative: MOTHER

Triage: Responsive/ HR /min BP mmHg RR /min SpO2 %
Unresponsive
Shifted to Paeds/ Main/ New Emergency

Presenting Complaints

Primary Assessment (ABCDE): Assessment Pentagon

<p>Airway</p> <p>Open & stable Yes/No If No.....</p> <p>Breathing: RR 20/min Efforts: Normal/Poor/increased</p> <p>Auscultation: Air entry: Normal/poor/Differential</p> <p>Added sounds: None/Stridor/Wheeze/Crackles</p> <p>SpO2 on Room air: 97%</p>	<p>Circulation</p> <p>HR 30/min CFT 2 secs. BP 113/82 mmHg</p> <p>Peripheral pulse: Poor/Good</p> <p>Central pulse: Poor/Good</p> <p>Skin temp: Warm/cool</p> <p>Others</p>	<p>Disability</p> <p>GCS 15/15 Pupil size 3mm/min Pupillary Reactions: RTL</p> <p>Motor activity: Normal & Symmetrical/Asymmetrical/ Posturing/Flaccidity/Seizure</p> <p>Blood Sugar 9 mg/dl Exposure Temp 98.8°F Colour: Normal/pallor/cyanosis/mottled Any other skin lesions.....</p>
--	--	--

Diagnosis

Burkitt lymphoma - red oral intake.

-VBG

-CBC

1400
9.5 / NO

3:00 PM

foot

Adm

1) IVF DNS @ 1:1000 cc @ 500 ml q8hrly

2) Med due to review.

[Signature]

d1-3

6. Inj. RITUXIMAB 400mg in 100

Pre Chemo

d1

Pre Meds

Inj. Avil - ~~100mg~~ 1 Amp

Inj. Hydro Cort - 100mg

T. Crocin - 1 Tab

7.

TIT

IT-MTX 12mg

IT-AAA-C 30mg

IT-HydroCort 15mg

Dated on
9/5/22
at 7:30 AM

8.

Inj. G-CSF

150mcg

slc on

7/5

9/5

10/5

9.

For with

CBC on

11/5/2022

Sanjeev Bhatnagar



डा. बी. आर. अम्बेडकर संस्थान रोटरी कैंसर अस्पताल
Dr. B.R. Ambedkar Sansthan Rotary Cancer Hospital
अ.भा.आ.स
बहिरंग
अस्पताल के अन्दर धुम

1000

No. 744 16/4/22

OPR-6

एक/Unit

विभाग/Dept.

↓ Dr. S.B. / Dr. D.P.
Med. Onc

नाम/Name

Divyansh

DR. B.R.A. HCH/ALIMS, NEW DELHI

HCH No. 272521

Clinic: Paed. Lymphoma Leukemia Clinic

Dept. MEDICAL ONCOLOGY

General

नाम दिव्यांश दिव्यांश

Name DIVYANSH

SG: RAJVEER

Phone No. 9990957398

Address G NGA, DAULAT PURA GZB, UTTAR PRADESH, INDIA

Reg. Date: 13/04/2022

Clinic No. 2022/20571



UHB-105911753

Sex/Age: M/10Y

Room: 13 (Shift Morning)

15911753

ate of Birth

निदान/Diagnosis

? Burkitt lymphoma. Staging awaited

दिनांक/Date

20/04/22

उपचार/Treatment

Puphax waf 18/04/22

AA1 + Rituximab

[waf 18/04/22]

cont HOMER

BNA - Not involved
provisionally

USF Rept - awaited
BM Biopsy

Tab. Desla 4mg od 1-0-0 [after food]
Tab. emeset 4mg 1-0-0 [3 days]
Tab. lammol TR 15mg od 1-0-0 [before food]

Drj. lfcse 150 mg b/c od x 5 days [from 21/04/22 - 25/04/22]

Syp. mernaaffon 3tsp. b/c (रात के 11 बजे के बाद से)

R/W CBC 15/04/22 24/04/22
(24/04/22) 24/04/22 बाहर से

Hom

Room No: 13

Sister Priya

03

23/4/22

Dr. 21/4/22
Dr. 22/4/22

अंगदान-जीवन का बहुमूल्य उपहार/ORGAN DONATION - A GIFT OF LIFE

O.R.B.O., AIIMS, 26588360, 26593444, www.orbo.org Helpline - 1060 (24 hrs service)

बाहर से आने वाले रोगियों के लिए धर्मशाला की सुविधा उपलब्ध है/Dharamshala facility is available for outstation patients

DISTRICT (M.M.G) HOSPITAL

G.T. ROAD, GHAZIABAD
DEPARTMENT OF PATHOLOGY
"AN ISO 9001:2015 CERTIFIED LABORATORY"

Date : 30-Apr-2022 Reg/Ref: MMG-168289 / 259277 Collected At : MMG
Name : MR. DIVANSH Age/Sex : 10 Yrs./Male
Ref.By : Dr. AVIDHESH KUMAR Phone : Ward : OPD
Receipt : NA
Coll Time : 30-Apr-2022 10:32 AM Validate : 30-Apr-2022 11:40 AM Prn. Time : 30-Apr-2022 11:40 AM

Investigation	Observed Values	Units	Biological Ref. Interval
---------------	-----------------	-------	--------------------------

HAEMATOLOGY

Complete Blood Count

Haemoglobin	8.7	g/dL	11.5 - 15.5
Total Leucocyte Count (TLC)	24900	cells/mm ³	4000- 11000
Differential % Leucocyte Counts:			
Neutrophils	85.8	%	40 - 80
Lymphocytes	6.7	%	20 - 40
MID Cells	7.5	%	1 - 6
Platelet Count	1.21	Lac cells/mm ³	1.5 - 4.5
LPCR	18.8	%	13.0 - 43.0
MPV	8.5	fl.	7.4 - 10.4
PDW	11.5	%	10.0 - 17.0
PCT	0.1	%	0.10 - 0.28
Total RBCs	3.09	Million cells/ μ L	4.5 - 5.5
MCV (Mean Cell Volume)	79.8	fl.	80 - 100
MCH (Mean Corpus. Haemoglobin)	28.3	pg	27 - 32
MCHC (Mean Corpus. Hb Conc.)	35.4	g/dl	32 - 35
HCT (hematocrit)	24.7	%	40 - 50
RDWA	64.9	fl.	37.0 - 54.0
RDWR	15.7	%	11.5 - 14.5
Absolute Leucocyte Counts:			
Abs. Neutrophils	21.4	thou/mm ³	1.63 - 6.96
Abs. Lymphocytes	1.6	thou/mm ³	1.03 - 2.99
Abs. Mid Cells	1.9	thou/mm ³	0.33 - 0.44

Pathologist



Checked By : Technician



डा. बी. आर. अम्बेडकर संस्थान रोटरी कैंसर अस्पताल
Dr. B.R. Ambedkar Sansthan Rotary Cancer Hospital

अ.भा.आ.स

बहिरंग र
अस्पताल के अन्दर धुम

OPR-6

एकक/Unit

विभाग/Dept.

↓ Dr. S.B / Dr. D.P

Med. Onc

नाम/Name

Divyansh

DR. B.R.A. ICHLAHMS, NEW DELHI

IRCH No. 272521

Clinic Paed. Lymphoma/Leukemia Clinic

Dept. MEDICAL ONCOLOGY

General

नाम दिव्यांश दिव्यांश

Name DIVYANSH

S/O- RAJVEER

Phone No. 9990957598

Address G NO-4, DAULAT PURA GZB, UTTAR PRADESH, INDIA

Reg. Date-13/04/2022

Clinic No. 2022/20571



UHID-105911753

Sex/Age M/10Y

Room 11 (Shift Morning)

Address G NO-4, DAULAT PURA GZB, UTTAR PRADESH, INDIA

5911753

ate of Birth

निदान/Diagnosis

? Burkitt lymphoma. Staging awaited

दिनांक/Date

20/04/22

उपचार/Treatment

BNA - Not involved
provisionally

USF report } - awaited
BM Biopsy }

Purpura w/f 14/04/22

AA1 + Rituximab

[w/f 18/04/22]

cont HDMtz

Tab. Dexam 4mg od 1-0-0 [after food]

Tab. emeset 4mg 1-0-0 [before food]

Tab. lammol IR 15mg od 1-0-0 [before food]

Inj. G-CSF 150 µg s/c od x 5days

[from 21/04/22 - 25/04/22]

Syp. memaffin 3tsp. hs (रात के नीचे के लीके लिए)

R/W CBC 1st test on 24/04/22
(24/04/22) 24/04/22 बाहर से

Amu

अंगदान-जीवन का बहुमूल्य उपहार/ORGAN DONATION - A GIFT OF LIFE

O.R.B.O., AIIMS, 26588360, 26593444, www.orbo.org Helpline - 1060 (24 hrs service)

बाहर से आने वाले रोगियों के लिए धर्मशाला की सुविधा उपलब्ध है/Dharamshala facility is available for outstation patients

RADIOLOGY UNIT

Dr. B. R. Ambedkar Institute Rotary Cancer Hospital
All India Institute of Medical Sciences, New Delhi-110029

Patient Name: Mr Divyansh Divyansh	Age/Gender: 10 Years and 0 Months / M
Patient UHID : 105911753	IRCH No : 272521
Accession No : 1085460	Location : MO WARD (7th Floor)
Date of Examination : 18-APR-2022 11:43 AM	

Procedure: CECT of Neck, Chest, Abdomen & Pelvis

Clinical background: suspected Burkitt's lymphoma

Neck: Normal. Note made of adenoid and tonsillar hypertrophy with no significant airway compromise

CHEST

Lung: Normal. No focal lesion.

Mediastinum: No lymph node enlargement.

Trachea/ bronchi: Normal

No pleural or pericardial effusion.

ABDOMEN

Diffuse enhancing sheet like soft tissue seen in RIF encasing the distal ileum, cecum, IC junction and ascending colon. No upstream dilatation of bowel loops. It is encasing the surrounding mesenteric vessels. Diffuse circumferential wall thickening and hyperenhancement of distal ileal loops in pelvis is also seen- noncontiguous with the right iliac fossa mass. Few mesenteric nodes are seen

Liver: 15.7 cm hepatomegaly. Focal area of hypodensity seen in segment 4b of liver likely focal fatty infiltration.

CBD/ intrahepatic bile ducts: Not dilated

Gall bladder: Normal

Pancreas: Normal

Spleen: Normal

Both Kidneys: Normal. No hydronephrosis. Multiple ill-defined hypoenhancing areas seen in left kidney
?focal pyelonephritis

Retroperitoneum/ vessels: normal

Free fluid: No ascites or pleural effusion.

Urinary bladder: Normal

Additional information: None

Comparison: None

Impression: Diffuse enhancing sheet like soft tissue seen in RIF encasing the distal ileum and cecum, IC junction and ascending colon; with non-contiguous ileal thickening as described

Radiologist: Dr. Lokesh (SR) / Dr. Ekta Dhamija



Department Of Pathology
All India Institute Of Medical Sciences
Delhi
Tel: +91-11-26588500/26588700; Fax: +91-11-26588500/26588700

Patient Name:	Divyansh	Acc. No:	2213298
F/H Name:	Rajveer	Hosp. Reg. No.:	0
Age/Sex:	70 Y/Male	UHID No.:	---
Clinic/Dept/Unit:	Dr. B.R. A. IRCH/Unit 1	Consultant Incharge:	Dr. Sameer Bakhshi
Reg Date:	16-04-2022	Reporting Date:	26-04-2022

Histopathology Report

Report Findings:

Received four paraffin embedded block and , six HE stained slide and four IHC slides for review sent as " lymphnode, appendix and ileum " (individual slides not labelled).

Section form ileum in four of slides shows multiple mucosal fragments with ulceration of mucosa with diffuse infiltration by intermediate size cell extending upto serosa.

The atypical cells are immunopositive for CD20, CD10, BCL6 cMYC while negative for cyclin D1. Bcl 2, CD3, tdt.

Ki 67 labelling index is approximately 95-100 %.

One of the slide show reactive lymphoid tissue and other one slide shows normal ileum.

Impression; Burkitt lymphoma

Reporting Incharge: Dr. Saumyaranjan Mallick

Reporting SR: Dr. Nitesh Rawat

Verify By: Dr. Nitesh Rawat



डा. बी. आर. अम्बेकर
Dr. B.R. Ambedkar
अ.भा.आ.र
वहिरंग
अस्पताल के अन्दर पु

संस्थान रोगी कैंसर अस्पताल
tal

272521

IRCH No. 275 DR. B.R.A. IRCH/ANMS NEW DELHI

Chief Oncology Screening OPD - Dr. Faculty SR IRCH
Dept. DR. BILARCHI ONCOLOGY SCREENING OPD
General

Reg. Date: 13/04/2022

Clinic No.

OPR-6

एकक/Unit _____

विभाग/Dept. _____

नाम/Name

DIVYANSH

नाम दिव्यांश दिव्यांश

Name DIVYANSH

S/O RAJEEV

Phone No. 9990917392



UHID-105911753

Date of Birth

Sex/Age M/10Y

Room Dr. BILARCHI (Shift Morning)

निदान/Diagnosis

tb-NHL

दिनांक/Date

उपचार/Treatment

5/2022

CC #1 - From 4/5

1. Inj. VCR 1.5mg ivp - d1 (4/5)

2. Inj. DEXONA 32mg in 100ml NS

d1-3

3. Inj. AAA-C in 100ml NS d1/d2
d1 → 2g ————— 2g (4/5)
d2 → 2g ————— 2g (5/5)

4. Inj. VP-16 in 200ml NS d2/d3
d2 → 250mg (5/5)
d3 → 200mg (6/5)



Dr. B.R. Ambedkar Institute Rotary Cancer Hospital
अ.भा.आ.सं. अस्पताल/A.I.I.M.S. HOSPITAL
बहिरंग रोगी विभाग/Out Patient Department
अस्पताल के अन्दर धूम्रपान मना है।/SMOKING PROHIBITED IN HOSPITAL PREMISES

OPR-6

IRCH No. 272521

एकक/Unit Dr SB/DP
विभाग/Dept. MO

ब०रो०वि० पंजीकृत सं०/O.P.D. Regn. No. 105911753

नाम/Name	पिता/पुत्र/पत्नी/पति/पुत्री F/S/W/H/D of	लिंग Sex	आयु Age	जन्म तिथि/Date of Birth
DIVYANSH		107	M	

निदान/Diagnosis Burkitt lymphoma, P/CC1 - 4/5/22 c FN - (R) pneumonia

दिनांक/Date

उपचार/Treatment

- Resolved.

Advice at discharge

17/5/22

T Lexim 200mg 1-0-1, Id सोत

ORs 200cc after each LM

C vizylac BD सोत

T Eureset 4 mg 1-1-1 सोत

T Pan 40mg 1-0-0

plenty of oral fluids सोत

to be on 23/05/2022 in OPD

to be on 21/5/22 c

Anura

अंगदान-जीवन का बहुमूल्य उपहार/ORGAN DONATION - A GIFT OF LIFE

O.R.B.O., AIIMS, 26588360, 26593444, www.orbo.org Helpline - 1060 (24 hrs service)

शहर से आने वाले रोगियों के लिए धर्मशाला की सुविधा उपलब्ध है/Dharamshala facility is available for outstation patients



भारत सरकार

Government of India



शीतल

Sheetal

जन्म तिथि/DOB: 17/04/1990

महिला/ FEMALE

8911 6765 2776

VID : 9156 4001



डा. बी. आर. अम्बेडकर संस्थान रोटरी कैंसर अस्पताल
Dr. B.R. Ambedkar Institute of Medical Sciences
अ.भा.आ.स.
बहिरंग र
अस्पताल के अन्दर धुम

OPR-6

एकक/Unit
विभाग/Dept.

↓ D.S.B / D.D.P

नाम/Name

Divyansh

DR. B.R.A. ICMH, AIIMS, NEW DELHI
Reg. Date-13/04/2022
Clinic No. 2022/20571
UHID-105911753
Sex/Age M/10Y
Room 13 (Shift Morning)
Address G NO-4, DAULAT PURA GZB, UTTAR PRADESH, INDIA

15911753
ate of Birth

निदान/Diagnosis

? Bunkitt lymphoma.

Staging awaited

उपचार/Treatment

BMA - Not involved
provisionally
USF report } - awaited
BM Biopsy

दिनांक/Date

Puphax wef 14/04/22

AA1 + Rituximab

[wef 18/04/22]

cont HOMTx

20/04/22

ht = 136cm
wt = 28.2kg
RA2 1.03m2

Room NO: 13

Sister Priya

Tab.

Desla.

4mg

od

[after food]

Tab.

emet

4mg

od

[before food]

Tab.

lanxol

15mg

od

[before food]

Inj.

lycSF

150 µg

o/c

od

x 5days

[from 21/04/22 -

Syp.

memaffin

3tsp.

hs

(रात के नीचे लेना)

R/W

CBC

फा फा

on

25/04/22

(24/02)

24/4/22 बाहर से

Homu

अंगदान-जीवन का बहुमूल्य उपहार/ORGAN DONATION - A GIFT OF LIFE

O.R.B.O., AIIMS, 26588360, 26593444, www.orbo.org Helpline - 1060 (24 hrs service)

बाहर से आने वाले रोगियों के लिए धर्मशाला की सुविधा उपलब्ध है/Dharamshala facility is available for outstation



डा. बी. आर. अम्बेडकर संस्थान रोटरी कैंसर अस्पताल
Dr. B.R. Ambedkar Institute Rotary Cancer Hospital
अ.भा.आ.सं. अस्पताल/A.I.I.M.S. HOSPITAL
बहिरंग रोगी विभाग/Out Patient Department
अस्पताल के अन्दर धूम्रपान मना है।/SMOKING PROHIBITED IN HOSPITAL PREMISES

OPR-6

एकक/Unit DSB/DP
विभाग/Dent. MO

IRCH No. 272521

ब०रो०वि० पंजीकृत सं०/O.P.D. Regn. No. 105911753

DR. B.R.A. IRCH, AIIMS, NEW DELHI
IRCH No. 272521
Clinic Paed. Lymphoma Leukemia Clinic
Deptt. MEDICAL ONCOLOGY
General
नाम दिव्यांश दिव्यांश
Name DIVYANSH
S/O- RAJVEEV
Phone No. 9990957398
Address G NO-4, DAULAT PURA GZB, UTTAR PRADESH, INDIA



UHID-105911753

Reg. Date-13/04/2022
Clinic No. 2022/20571
Sex/Age M/10Y
Room 13 (Shift Morning)

ल/पति/पुत्री H / D of	लिंग Sex	आयु Age	जन्म तिथि/Date of Birth
	107	M	

na, P/CC1 - 4/5/22 c FN - (R) pneumonia

उपचार/Treatment - Resolved.

17/5/22

Advice at discharge

T ~~taxim~~ ^{खाने के} taxim 200mg 1-0-1 x 7d ^{सात दिन तक}

ORs 200cc after each LM

C Vizylac BD ^{खाने से पहले}

T Emeset 4 mg ^{खाने के बाद}

T Pan 40mg 1-0-0

plenty of oral fluids ^{जो का पानी दें}

fv on 23/05/2022 ch OPD

to fv in hft OPD on 21/5/22 c CB/RS/UR
Anura.

Sister Priya

21/5/22

CBC:OK

Hu in OPD

✓



डॉ. बी. आर. अम्बेडकर सरस्थान रोटरी कैंसर अस्पताल
Dr. B.R. Ambedkar
अ.भा.आ.सं.
बहिरंग रोग
अस्पताल के अन्दर धुम्रपात्र

Address G NO-4, DAULAT PURA GZB, UTTAR PRADESH, INDIA
DR. B.R.A. IRCH, AIIMS, NEW DELHI
IRCH No. 272521
Clinic Oncology Screening OPD - Dr. Faculty/ SR IRCH
Deptt. DR BRAIRCH ONCOLOGY SCREENING OPD
General
Reg. Date-13/04/2022
Clinic No.

OPR-6

एकक/Unit Dr 505/DP
विभाग/Dept. med

नाम/Name

DIVYANSH

नाम दिव्यांश दिव्यांश
Name DIVYANSH
S/O- RAJEEV
Phone No. 9990957308



UHID-105911753

CKID-62034

te of Birth

Sex/Age M/10Y

Room Dr. BRAIRCH (Shift: Morning)

निदान/Diagnosis

B-NHL

दिनांक/Date

11/5/2022

उपचार/Treatment

CC#1 - 2#8

DI
11/5/2022

द्वारा

15

D2 (M) + CRF
12/5/2022 (E)

Inj. MAGNEX 3gm IV Bid
Inj. AMIKACIN 400mg IV OD
Inj. G-CSF 150mcg SC OD
5 days

Fv with CBC on 12/5

Sameer

Cont Mag/Amikex 1 G-CSF
x 5 day

12/5/2022


BT-10


Fv with CBC + LFT/RFT on 19/5

25/4/2022

Cont G- CSF X 4 day - (25/4) full 02/27/4

Fr with CBC + LFT/RFT
on ~~25/4/2022~~ 28/4

T. 2 after 4mg  X 3 day



28/4/2022

Fr with CBC + LFT/RFT on 01/5/20
2/5
over

